

# Scapula Fracture Secondary to Static Line Injury in a 22 year-old Active Duty Soldier

LTC W. David Thompson, MPAS, PA-C

## ABSTRACT

This radiological case study of scapula fracture is reported in a 22 year-old active duty male Soldier who sustained a static line injury during an airborne operation at Fort Bragg, North Carolina. This is the first reported scapula fracture secondary to this mechanism since a 1973 report by Heckman and Levine. The fracture was neither identified by Emergency Department nor Orthopedic Surgery providers, and was reported in the radiologist's formal read. Ten emergency physicians and emergency medicine physician assistants reviewed the radiographical studies and none successfully identified the injury. Because this injury was uniformly missed by experienced emergency medicine providers it is presented as a radiographic case study in hopes that this injury will not go undiagnosed, potentially causing increased morbidity and mortality in this patient population. The patient was treated with a posterior splint and immobilization and seen by the orthopedic service the next day. Interestingly, the orthopedic surgeon also did not recognize this fracture. This mechanism of injury is rarely seen in clinical practice outside of the airborne community. Scapula fractures can be an indicator of serious thoracic trauma and may prompt the need for further diagnostic studies. The fact that so many providers missed the injury reinforces the need to evaluate the patient as a whole and to be ever suspicious of missing concomitant injuries in the trauma patient.

**Key Words:** Scapula Fracture, Emergency Department, Orthopedic, Radiograph, Airborne

## BACKGROUND

A static line injury to the military parachutist's arm usually results in a closed transaction of the belly of the bicep's brachii muscle. This is an uncommon injury in the civilian community, but one that is seen several times a year in military treatment facilities that provide care to units conducting static line parachute operations. In United States military airborne operations, the vast majority of personnel are delivered to the battlefield by exiting, usually from a United States Air Force aircraft flying over a drop zone utilizing a T-10 or MC-1 series parachute. Prior to exiting the aircraft, each parachutist "hooks up" his static line to an anchor line cable running from the forward to aft section of the aircraft. As the parachutist exits and falls away from the aircraft, a 15 foot (4.572m) universal static line constructed of yellow nylon (with a tensile strength of 3,600 pounds [1632.9kg]) deploys the main canopy of the parachute away from the parachute pack tray. The parachute elongates, a break cord tie securing the apex of the canopy to the static line end loop breaks and the parachute begins to inflate, slowing the parachutist's rate of descent and ideally delivering the parachutist safely to the ground to complete his mission.<sup>1</sup>

Static line injuries occur when a static line wraps around the arm of the parachutist as he exits the door of the aircraft. Generally this occurs when a parachutist exits the aircraft with the static line misrouted under his arm (Figure 1). The misrouted static line wraps around the arm of the jumper causing injury. This may also occur if the preceding jumper throws his static line at the "safety" (member of the jumpmaster team responsible for ensuring static lines are safely pushed to the rear of the aircraft and are clear of the doorway as jumpers exit). When this occurs, the static line tends to ride

low in the trail edge of the door. As the next jumper hands his static line to the safety and turns to exit the aircraft, the preceding jumper's static line, now rising to the upper portion of the trail edge of the paratroop door wraps around the arm of the second parachutist, causing injury (Figure 2).

## CASE REPORT

A 22 year-old white male presented to the Emergency Department after transport by ambulance from Sicily Drop Zone after participating in a nighttime, mass tactical parachute jump during a Joint Forced Entry Exercise conducted at Fort Bragg, North Carolina. The patient was the twentieth jumper to exit from the right paratroop door of a U.S. Air Force C-130 aircraft. The patient was equipped with a rucksack and M-4 Carbine. The static line wrapped around his right bicep. The



**Figure 1:** *Static line misrouted under arm.*



**Figure 2:** Previous jumpers static line looped around jumpers arm. This occurs when the previous jumper drops or throws his static line to the safety or when the safety loses control of the static line.

patient did not recall hitting the side of the aircraft. He did not recall landing on his shoulder. The patient was unable to pack up his parachute, gather his equipment or move to his unit's assembly area. The patient was found by medics on the drop zone, placed in a SAM splint and sling and transported to the Emergency Department at Womack Army Medical Center.). He was complaining of right arm and shoulder pain. He did not complain of back pain. He denied other injury. Vital signs were: temperature 98.1, Pulse 61 bpm, blood pressure 128/90 mmHg, respiratory rate 20 bpm, and oxygen saturation 100%. The patient was alert, in no acute distress, but in obvious pain. His physical examination demonstrated markedly decreased range of motion of the right shoulder and elbow. He had an area of ecchymosis that measured approximately 20 centimeters long by 10 centimeters wide over the mid portion of his right bicep. He had an area of ecchymosis and abrasion to his anterior chest just inferior to his right clavicle. His clavicle was non-tender to palpation. His forearm was non-tender. All of his forearm compartments were soft. His mid bicep was very tender to palpation. He had no bony tenderness over his shoulder, neck or back. His wrist and hand were normal in appearance, non-tender to palpation and moved normally. Capillary refill was less than two seconds. The remainder of his physical examination was within normal limits.

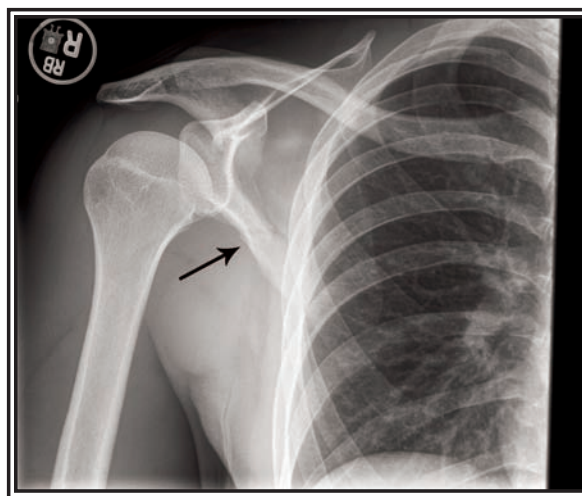
Conventional radiographs of the chest, shoulder, humerus, and forearm were ordered and performed in the radiology department. A peripheral IV was established and he was given 1mg of hydromorphone and 4mg of ondansetron intravenously for pain and nausea with partial relief. A repeat dose of 1mg hydromorphone was given that relieved his remaining pain.

The patient's radiographs were reviewed by the ED clinician. No obvious fractures were identified and orthopedic surgery was consulted. The diagnosis of biceps rupture secondary to static line injury was made. The patient was placed in a long arm splint in flexion with the hand in pronation to unload the biceps muscle. He was discharged with instructions to follow up the next morning with orthopedic surgery. The radiologist later over-read the images, and identified a cortical irregularity of the lateral aspect of the mid scapula (Image 1). This was read as a possible fracture of the lateral aspect of the mid-scapula. At this point, the attending orthopedic surgeon was consulted by the ED provider. On review of the patient's radiographs, the orthopedist agreed with the radiologists findings and did not think the biceps injury was operative in nature; the patient was referred to occupational therapy for treatment. He did not feel the scapula fracture would need any treatment other than pain management and observation. The patient continues to follow with occupational therapy and is doing well. Follow up radiographs (Image 2 and 3) show a healing scapula fracture with well defined bony callous.

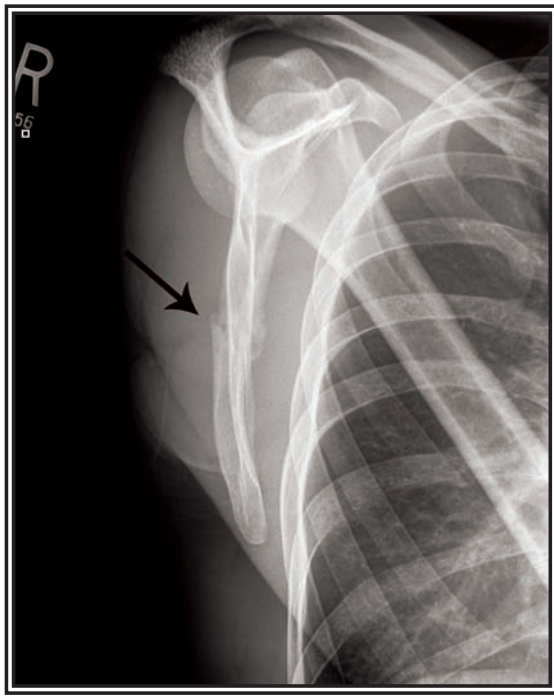
## DISCUSSION

Static line injuries to the upper extremity can be manifest as several different types of injury, from fractures of both bones of the arm to partial amputation of the hand. The most common site of injury is to the anterior, mid portion of the arm over the bicep muscle. The skin will show some contusion and abrasion, but generally no laceration. There is marked swelling and localized pain over the belly of the bicep immediately following injury. A palpable defect is usually felt with the mid bicep.<sup>2</sup>

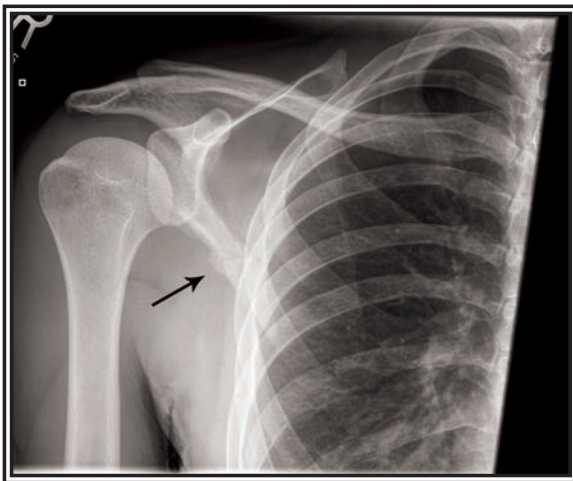
Static line injuries have previously accounted for 2.2% of all parachuting injuries in one study involving U.S. Army Rangers by Kragh et al., in 1996.<sup>3</sup> This is quite different than Hughes' study of 4th Battalion Royal Australian reg-



**Image 1:** Anterior-posterior view of patient's right shoulder. Note the non-displaced fracture of the body of the scapula. This is very hard to see. Notice the cortical irregularity and radiolucent line extending from the lateral border of the scapula.



**Image 2:** Scapular-Y view taken approximately three weeks post injury. Note the obvious fracture and bony callous formation.



**Image 3:** Three week post injury anterior posterior view of the shoulder demonstrates a healing scapular body fracture with bony callous formation.

iment (Commando) in which no soldiers sustained a static line injury. The smaller rate of injury is likely secondary to a relatively small number of overall jumps (706 jumps by 254 paratroopers, only 49.5% of which were with combat equipment). The fact that this injury was one of two static line injuries from the same aircraft during a summer time JFEX (nighttime, mass tactical, combat equipment, high ambient temperature with follow-on mission) supports the claim by Knapik in his 2003 paper that more complex operations tend to have higher casualty rates overall.<sup>4</sup> Bricknell and Craig

conducted a literature review of military parachuting injuries in their 1999 paper. Review of the literature at that time listed Neel's 1951 study of 1,012 parachuting injuries as having a 0.4% rate of scapula fracture, but it does not state whether this injury was caused by a static line injury or not.<sup>5,6</sup> Ciccone and Richmann's 1948 study reports a scapula fracture rate of 0.2% in 3,015 parachute jumps, again, not stating whether these injuries were secondary to static line injuries or not.<sup>7</sup>

The Department of Emergency Medicine of Womack Army Medical Center saw a total of 429 patients with jump injuries coded by ICD 9 code. Of these 429 patients, 22 or 19.5% had a shoulder or biceps injury. A review of ICD 9 codes related to jump injury showed 647 total jump injuries in all Fort Bragg clinics combined. Two scapula fractures secondary to jump injuries were seen in 2009, but both were the result of hard landings, rather than static line injuries.

#### EMERGENCY DEPARTMENT MANAGEMENT

Isolated static line injuries can usually be managed as an outpatient. Initial evaluation in the Emergency Department begins with a complete history and physical examination. The examination should especially focus on identifying concomitant injuries as well as motor and sensory neurological deficits. Physical examination should especially focus on the entire affected extremity, neck, back, and chest. Close attention to neurovascular status and confirmation of soft compartments is critical. Radiographs should include anterior/posterior views of the shoulder as well as lateral and scapula-Y views. Humerus and elbow films are needed. A chest radiograph is absolutely required. A scapula fracture can be well visualized on CT. Outpatient management of pain can usually be controlled with oral medications such as oxycodone/acetaminophen combinations, acetaminophen with codeine or ibuprofen. Patients with transected biceps muscles secondary to static line injury should be placed in a posterior splint with the elbow flexed to 45 degrees and the forearm in pronation to unload the bicep. Consultation with orthopedics in the emergency department may be indicated. Patients definitely should be seen by orthopedics in follow-up within the next several days.

#### SCAPULA FRACTURE MANAGEMENT

This case is unique in that the patient sustained a scapular body fracture in addition to his transected biceps brachii. This injury is especially significant because it appears that this injury occurred from a distraction type injury. Most scapula fractures occur from blunt force trauma and usually this trauma is almost always point focused. There is only one prior reported case of scapula body fracture secondary to a static line injury, reported by Heckmann in 1978.<sup>8</sup> Scapula fractures are clinically significant in that up to 80-90% of patients will have an associated injury (Table 1).<sup>9</sup> The importance of evaluating multi-trauma patients with scapula fractures cannot be over-emphasized. Veysi et al., found in one retrospective study that presence of scapula fracture was a significant marker for severe underlying trauma, with an Injury Severity Score (ISS) of 27.12 in trauma patients with

scapula fracture versus 22.8 in patients without scapula fracture.<sup>10</sup> CT Scanning is an excellent tool for evaluation of the scapula as well as for imaging underlying pathology, especially injuries to the chest that may otherwise be missed. All patients diagnosed with scapula fracture on plain film should undergo CT scanning of the chest and abdomen with oral and intravenous contrast to rule underlying pathology.

The vast majority of scapular body fractures can be treated non-surgically. Closed reduction of these fractures is usually not possible. Treatment usually consists of a sling for support and early motion. Most of these fractures will heal in six weeks.<sup>11</sup> Indications for surgical management of scapular fractures includes: fracture of the scapular neck with greater than one centimeter of displacement, fractures of the glenoid lip or fossa, fracture with acromial involvement, fracture of the scapula neck with associated coracoid involvement.

### CONCLUSION

Static line injury is a preventable occurrence. Unfortunately, it continues to cause significant morbidity amongst some of the nation's most outstanding warriors every year. As this unusual case shows, not all static line injuries simply affect the biceps brachii muscle. The provider must consistently search for associated injuries and look at the patient as a whole rather than concentrating on what appears to be an isolated injury.

Scapula fracture is a significant indicator of serious underlying pathology in trauma patients. These patients should undergo CT scanning of the chest to rule out underlying injury as well as further define the extent of the scapula fracture. Other injuries associated with static line injury include pectoralis major tear, biceps tendon avulsion, and fractures of the long bones of the upper extremity. Prompt evaluation of patients by orthopedics is a must, but may be done as an outpatient.

Pulmonary Injuries	
Pneumothorax and Pulmonary Contusion	23%
Clavicle Fracture	
Floating Shoulder Injury	23%
Shoulder Dislocation	
Brachial Plexus Injury	
Axillary Artery Injury	

Military healthcare providers assigned to airborne units should monitor pre-jump training and ensure that static line injury prevention is particularly stressed by the jump-master team. Individual paratroopers are responsible to themselves and their unit to ensure they practice good technique when conducting airborne operations to ensure that their actions do not cause injury to their fellow Soldiers.

### ACKNOWLEDGEMENTS

Photos with the permission of the individual Soldiers. The author would like to thank COL Frank Christopher, MD, CPT (P) George Barbee, DSc, PA-C, Dr. Paul Kleinschmidt, MD, FACEP and Dr. James Santangelo and Mr. Thomas Butler PA-C for their assistance in reviewing this article.

### REFERENCES

1. FM 3-21.220 Static Line Parachuting Techniques and Training, September 2003, Headquarters, Department of the Army.
2. Heckmann, JD; Levine, MI. (1978). Traumatic closed transection of the biceps brachii in the military parachutist. *J Bone Joint Surg*, 60:369-372.
3. Kragh, JF Jr; Jones, BH; Amaroso, PJ; Heekin, RD. (1996). Parachuting injuries among Army Rangers: A prospective survey of an elite airborne battalion. *Mil Med*, Jul;161(7):416-9.
4. Knapik, Joseph; Craig, Stephen; Hauret, Keith; Jones, Bruce. (2003). Risk factors for injuries during military parachuting. *Aviation, Space and Environmental Medicine*, Volume 74, No. 7, July.
5. Bricknel, MCM; Craig, SC. (1999). Military parachuting injuries: A literature review. *Occupational Medicine*. Vol 49, No. 1, pp, 17-26.
6. Neel, SH. (1951). Medical aspects of military parachuting. *Milit Surg*, 108: 91-105.
7. Ciccone, R; Richman, RM. (1948). The mechanism of injury and the distribution of three thousand fractures and dislocations caused by parachute jumping. *J Bone Joint Surg*, 30A: 77-97.
8. Ibid.
9. Retrieved from [http://www.wheelessonline.com/ortho/scapular\\_fractures](http://www.wheelessonline.com/ortho/scapular_fractures).
10. Veysi, VT; Mittal, R; Agarwal, S; Dosani, A; Giannoudis, PV. (2003). Multiple trauma and scapula fractures: So what? Department of Trauma and Orthopaedics, St James' University Hospital, Leeds, United Kingdom. *Journal of Trauma*, Dec;55(6):1145-7.
11. Retrieved from [http://www.wheelessonline.com/ortho/scapular\\_fractures](http://www.wheelessonline.com/ortho/scapular_fractures).

LTC David Thompson, MPAS, APA-C is a physician assistant in the Department of Emergency Medicine at Womack Army Medical Center. He is a 1997 graduate of the Bowman Gray School of Medicine of Wake Forest University. LTC Thompson is currently the commander of the 7236th Installation Medical Support Unit at Fort Bragg, NC. He has previously served in USASOC and USSOCOM, as well as the 82D Airborne Division, 44th Medical Brigade, and the 10th Mountain Division. His operational deployments include Operation Uphold Democracy and Operation Enduring Freedom.