

Noninvasive Reduction of Open-Book Pelvic Fractures by Circumferential Compression

Michael Bottlang, *Tamara Simpson, Juergen Sigg, James C. Krieg, Steven M. Madey, and William B. Long

*Biomechanics Laboratory, Legacy Health System, and *Oregon Health Sciences University, Portland, Oregon, U.S.A.*

Objectives: To determine the efficacy and optimal application parameters of circumferential compression to reduce external rotation-type pelvic fractures.

Design: Biomechanical investigation on human cadaveric specimens.

Setting: Biomechanics laboratory.

Intervention: Partially stable and unstable external rotation injuries of the pelvic ring (OTA classification 61-B1 and 61-C1) were created in seven human cadaveric specimens. A prototype pelvic strap was applied subsequently at three distinct transverse levels around the pelvis. Circumferential pelvic compression was induced by gradual tensioning of the strap to attempt complete reduction of the symphysis diastasis.

Main Outcome Measurements: Pelvic reduction was evaluated with respect to strap tension and the strap application site. The effect of circumferential compression on intraperitoneal pressure and skin–strap interface pressure was measured.

Results: A successive increase in circumferential compression consistently induced a gradual decrease in symphysis diastasis. An optimal strap application site was determined, at which circumferential compression most effectively yielded pelvic reduction. The minimum strap tension required to achieve complete reduction of symphysis diastasis was determined to be 177 ± 44 Newtons and 180 ± 50 Newtons in the partially stable and unstable pelvis, respectively.

Conclusions: Application of circumferential compression to the pelvic soft tissue envelope with a pelvic strap was an efficient means to achieve controlled reduction of external rotation-type pelvic fractures. This study derived application parameters with direct clinical implication for noninvasive emergent management of traumatic pelvic ring disruptions.

Key Words: Pelvic ring disruption, Hemorrhagic shock, Emergent care.

Unstable pelvic fractures are associated with a high incidence of morbidity and mortality (9,16,18,25,33), with hemorrhage being the leading cause of death (7,10,22). Although the source of hemorrhage can be from multiple sites, the degree and type of pelvic disruption directly correlate with retroperitoneal blood loss (6,11,16,26). Even though a limited set of treatment modalities for hemodynamically unstable patients with unstable pelvic fractures is available, no general consensus exists regarding the optimal methods of emergent management. Several authors have proposed treatment algorithms for the management of life-threatening hemorrhage in pelvic trauma (3,16,18,19,25,27,28,29). These management schemes include fluid resuscitation, correction of coagulopathy, selective angiography, and temporary pelvic re-

duction and stabilization. Among these, pelvic reduction and stabilization in the early post-traumatic phase are reported to provide the most effective means of controlling venous hemorrhage (3,8,13,27). Pelvic reduction realigns bleeding fracture surfaces, whereas pelvic stabilization facilitates clot formation by reducing fracture site motion (14). Despite the potential benefits of such intervention, few devices for emergent, noninvasive pelvic reduction and stabilization at the accident site are available (34).

Current treatment options for immediate pelvic stabilization include open reduction and internal fixation (ORIF) (32,35), closed reduction and percutaneous fixation (27), external fixation (25), posterior pelvic reduction clamps (13), inflatable pneumatic trousers (2), and circumferential wrapping of the pelvic region with a sheet or strap (28,34). All of these approaches exhibit potential problems in an emergent situation. ORIF and percutaneous fixation have the potential to provide superior reduction and the most stable fixation, yet are invasive, require an operating room environment, and may delay angiography (27,32,35). In addition, ORIF may release the evolving pelvic hematoma. Anterior external fixation has inherent deficiencies in reducing and

Accepted July 9, 2001.

Address correspondence and reprint requests to Dr. Michael Bottlang, Legacy Clinical Research & Technology Center, 1225 NE 2nd Avenue, Portland, OR 97232, U.S.A.

Supported by a grant from the Legacy Research Advisory Committee. The authors have received nothing else of value.

The device that is subject of this manuscript is not FDA approved and is not commercially available in the United States.

stabilizing posterior pelvic disruptions (15,20,24). Pelvic antishock clamps may be difficult to apply and have caused severe complications (14,19). Inflatable pneumatic trousers limit access to critical areas of interest in the polytraumatized patient, namely, the perineum and abdomen. They can cause systemic complications (4,16,21), and their pressurization has been associated with compartmental syndromes in the lower extremities (12,17,21). Most recently, the use of circumferential pelvic sheets and straps for reduction and stabilization of pelvic fractures has been reported (3,27,28,34). The noninvasive nature of these devices minimizes the risk of serious complication and allows application at the emergency site. Although this technique has recently been recommended by the American College of Surgeons Committee on Trauma (1), no data are available to describe the application, efficacy, and safety of circumferential pelvic compression to unstable pelvic fractures.

We conducted a cadaveric, biomechanical investigation on the effectiveness of a noninvasive pelvic strap to induce pelvic reduction by means of circumferential compression. We attempted to determine the most effective strap application site as well as the strap tension required to reduce a partially stable and unstable cadaveric pelvic fracture model.

MATERIALS AND METHODS

Four male and three female nonembalmed whole body cadaveric specimens were used, ranging in age from seventy-three to ninety-three years with an average age of 79.7 years. The average specimen height was 170 centimeters, ranging from 157 to 185 centimeters. The body mass index ranged from 21.7 to 30.8 kilograms per square meter with an average value of 25.7 kilograms per

square meter (normal body mass index range 19 to 25 kilograms per square meter). Each specimen was instrumented with three different sensing devices as shown in Figure 1. Two six-degrees-of-freedom motion tracking sensors (pcBird, Ascension Tech. Corp., Burlington, VT, USA) were rigidly mounted on the superior pubic rami in a parasymphyseal location, using custom-built nonferromagnetic mounting clamps. These sensors were used to assess the spatial location and motion of each hemipelvis. These hemipelvic kinematics data, in combination with coordinate digitization on the superior symphyseal region, allowed us to compute the apparent displacement vector d_s at the pubis symphysis. Furthermore, a symphysis pubis sensor was designed to detect the symphyseal contact that occurred with complete reduction of symphysis diastasis. This sensor determined electrical conductivity between two metallic films that were fitted to each osteotomy surface after symphysiotomy. Finally, intraperitoneal pressure was monitored with a pressure sensor (HP 78534, Hewlett Packard, Englewood, CO, USA). To obtain reproducible and reliable recordings, this sensor measured the pressure inside a fifty-cubic centimeter fluid-filled pressure pouch, which was surgically inserted into the intraperitoneal cavity. After specimen instrumentation the pelvic ring was weakened in a defined manner to achieve reproducible fractures. Anteriorly, a complete symphysiotomy was performed. Posteriorly, the left sacroiliac ligaments and joint capsule were exposed via an anterior approach and surgically transected. Subsequently, two distinct unilateral pelvic ring fractures were induced by forced external rotation of the left hemipelvis (Fig. 2). For this purpose one-inch-wide belts were inserted through each obturator foramen. Lateral tensioning of these belts was manually applied with the aid of a lever arm. The motion tracking system

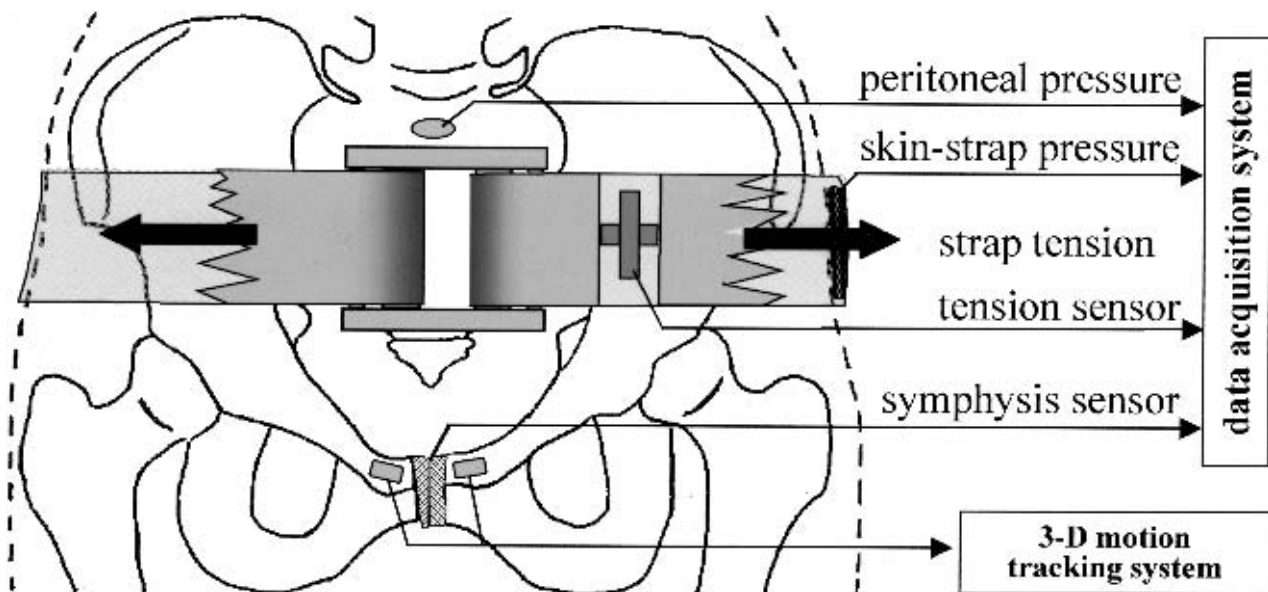


FIG. 1. Instrumentation of specimens and pelvic strap for assessment of intraperitoneal pressure, strap tension, skin-strap interface pressure, symphysis contact, and spatial motion of each hemipelvis.

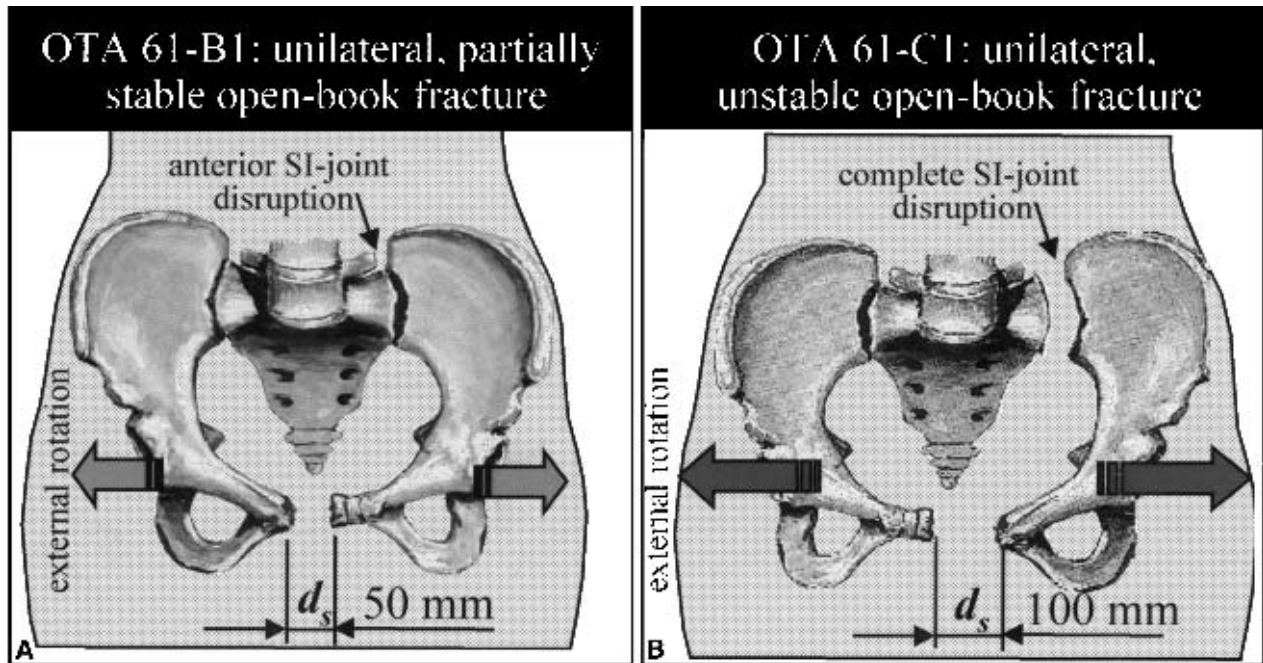


FIG. 2. Consecutive open-book fracture model, subsequently simulating two distinct injury severity patterns, corresponding to OTA classifications 61-B1 and 61-C1.

was used to provide continuous feedback of the apparent symphysis diastasis. First, a partially stable external rotation fracture (OTA classification 61-B1) was modeled as having a symphysis diastasis of fifty millimeters with unilateral disruption of the anterior sacroiliac joint. This fracture was subsequently expanded to an unstable pelvic fracture (OTA classification 61-C1) characterized by 100-millimeter symphysis diastasis and complete unilateral sacroiliac joint disruption.

An experimental prototype pelvic strap was designed, consisting of a fifty-millimeter-wide, flexible, nonelastic rubber strap, which encircled the pelvis and was guided

anteriorly over rollers contained in a buckle (Fig. 3a). Manual application of tension F_T to the ends of the strap gradually induced circumferential pelvic compression. Two sensors were integrated into the strap to provide real-time assessment of the applied strap tension (ELFS-500N, Entran, Fairfield, NJ, USA) and the resulting lateral strap-skin interface pressure (HP 78534, Hewlett Packard, Englewood, CO, USA). For each specimen the strap was applied in three distinct transverse plane levels around the pelvis (Fig. 3b). At transverse plane level I the pelvic strap was located to circumscribe the symphysis pubis and the greater trochanteric region. Transverse

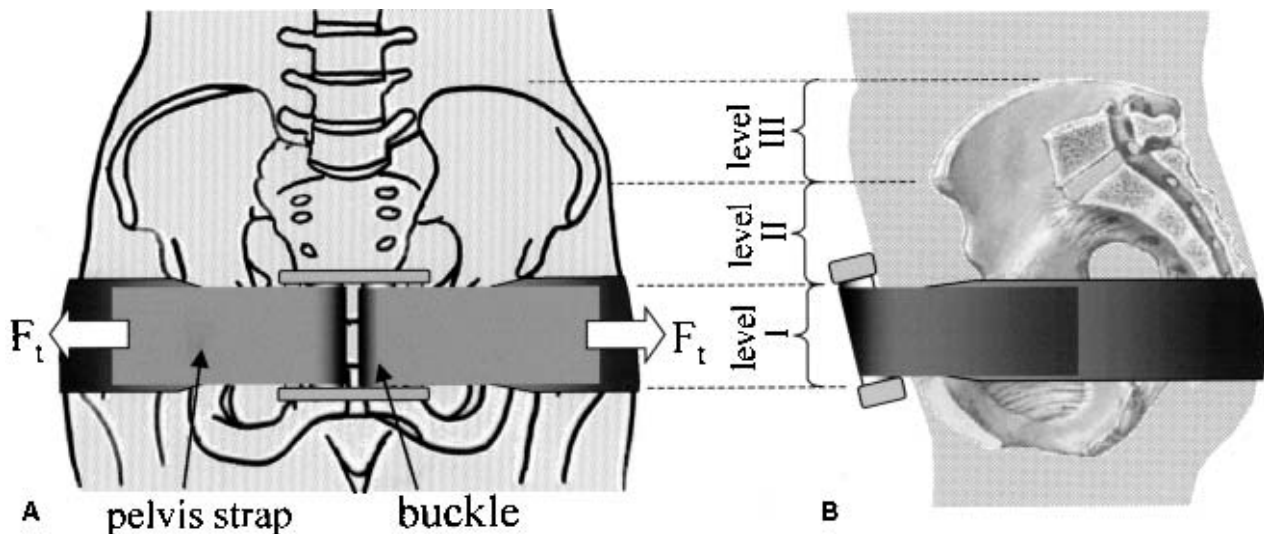


FIG. 3. Independent experimental variables of the pelvic strap. **a:** Strap tension F_T . **b:** Application levels I to III.

level II was centered midway between the symphysis pubis and the iliac crest. At transverse level III the pelvic strap was applied between the anterior–superior iliac spine and the iliac crest. Anteroposterior fluoroscopic visualization was used to ensure proper strap placement. Circumferential pelvic compression was induced manually by gradual application of laterally directed tension to each strap end. The pelvic strap was first applied to reduce the partially stable, and subsequently, the unstable pelvic fracture. Resulting strap tension, intraperitoneal pressure, strap–skin interface pressure, and spatial motion of the hemipelvis relative to each other were simultaneously recorded (SCXI 1000, National Instruments, Austin, TX, USA) until symphysis contact was detected. Finally, fracture patterns were documented on pelvic anteroposterior as well as inlet and outlet radiographs, obtained for each specimen before and after fracture reduction. In addition, a computerized tomographic (CT) scan of one specimen was obtained before and after reduction of the unstable pelvis to visualize pelvic ring congruity in the transverse plane.

Outcome parameters were statistically analyzed using a two-tailed *t* test for paired samples. Statistical significance was determined at $\alpha < 0.05$, and mean and standard error of the mean were documented.

RESULTS

Fluoroscopic radiographs of the pelvis demonstrated consistent and graded pelvic ring fractures in each of the seven specimens (Fig. 4). Motion tracking recordings yielded a symphyseal diastasis at the time of maximal pelvic disruption of 56.2 ± 6.4 millimeters for the partially stable pelvis and 99.0 ± 5.8 millimeters for the unstable pelvis. After release of the disruption force, a stress–relaxation recoil behavior of the pelvis was observed accompanied by a significant decrease in symphysis diastasis. This pelvic relaxation reached a steady state after about sixty seconds, at which time the symphysis diastasis of the partially stable and unstable pelvis

decreased by 50.1 ± 14.8 percent and 54.3 ± 7.2 percent, respectively (Fig. 5).

With pelvic strap application, a continuous increase of strap tension F_T up to 200 Newtons induced a gradual decrease in displacement d_s at the pubis symphysis (Fig. 6). After closure of symphysis diastasis, detected by the symphysis contact sensor, the residual symphyseal misalignment in the sagittal plane was $d_s = 5.8 \pm 3.6$ millimeters for reduction of the unstable pelvis by strap application at level I. In this scenario closure of symphysis diastasis was achieved at a strap tension of 177 ± 44 Newtons for the partially stable pelvis and 180 ± 50 Newtons for the unstable pelvis (Fig. 7). Symphysis diastasis closure due to strap application at levels II and III required a significantly higher strap tension of 228 ± 55 and 262 ± 79 Newtons, respectively.

Reduction of the unstable pelvic fracture by strap application at level I was characterized by an intraperitoneal pressure increase of 6.2 ± 5.8 millimeters of mercury and a strap–skin interface pressure of twenty-four millimeters of mercury. Pelvic reduction by strap application at levels II and III caused an intraperitoneal pressure increase of 19.4 ± 13.8 and 20.9 ± 13.2 millimeters of mercury, respectively.

CT images of one specimen obtained at levels of the fifth lumbar vertebra and the symphysis pubis demonstrated that strap application at level I effectively induced circumferential soft tissue compression, which evoked near-anatomic reduction of the sacroiliac joint and the symphysis pubis (Fig. 8).

DISCUSSION

Unstable pelvic ring disruptions benefit from emergent reduction and stabilization, aimed at controlling retroperitoneal hemorrhage (8,12,23,26,27). While initial clinical results obtained with pelvic sheets and straps have been encouraging, published information remains rare and a biomechanical technique evaluation has been absent. Vermeulen et al. (34) reported the application of

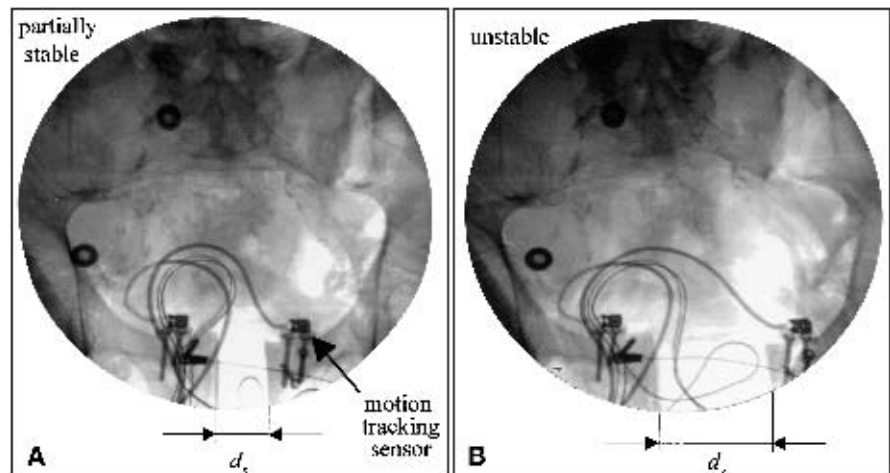


FIG. 4. Anteroposterior fluoroscopic radiographs of the partially stable (a) and unstable (b) pelvic fracture model, obtained after recoil of the pelvic ring.

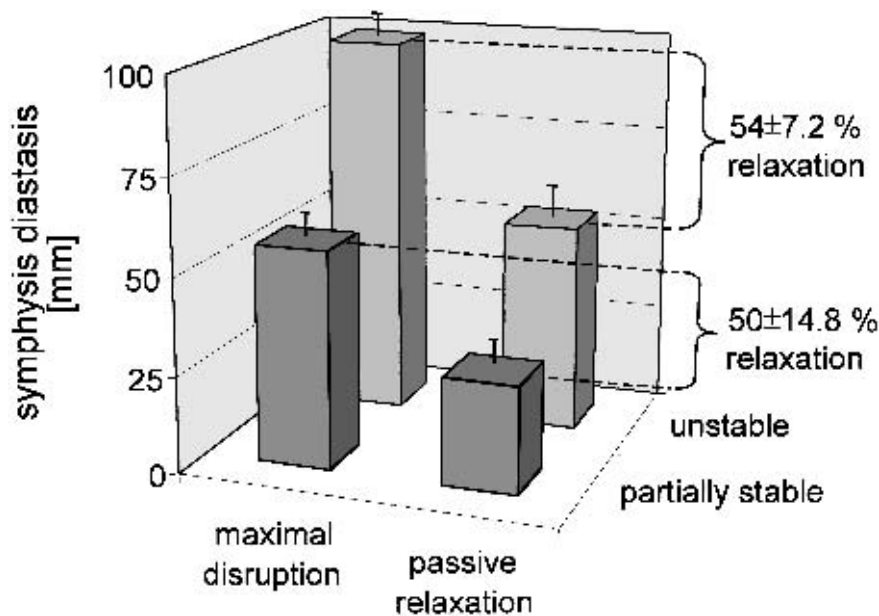


FIG. 5. Passive relaxation of the pelvic ring, measured sixty seconds after forced, maximum external expansion up to a symphysis diastasis of 56.2 ± 6.4 millimeters and 99 ± 5.8 millimeters in the partially stable and unstable pelvic fracture model, respectively.

a pelvic strap to nineteen patients with pelvic injuries. Their pelvic strap was applied at the accident scene by paramedics upon suspicion of unstable pelvic lesions. Two of their patients showed no abnormalities on initial pelvic radiographs obtained with the strap in place. However, a four-centimeter opening of the symphysis pubis appeared after strap removal, and associated sacrum fractures were present in both cases. They reported a pelvic strap application time of approximately thirty seconds and emphasized significant time savings compared with the use of pneumatic garments (34). Rouff et al. (28) encircled the pelvic region of one hemodynamically unstable patient with bilateral pubic ramus fractures and sacroiliac joint disruptions in a snugly applied sheet. The sheet was applied in the angiography suite. They emphasized the importance of early stabilization by circumferential pelvic compression but pointed out the potential damage to nerve roots that can be caused by overcompression

in patients with sacral foramina fractures. However, no detailed information on the amount of applied pelvic compression or its application site has been reported.

This research delineates for the first time the application and efficacy of this noninvasive pelvic stabilization approach in a biomechanical study on cadaveric specimens. Our study design was based on established fracture models. Unstable unilateral open-book fractures in denuded pelvic specimens have previously been created to assess the rigidity provided by external fixation frames (5) and ORIF (30,31). Brown et al. (5) concluded that supplementary support from soft tissue is an important factor in successful clinical modeling of pelvic ring rigidity. Ghanayem et al. (14) used specimens with an intact soft tissue envelope to create unilateral open-book pelvic fractures by direct dissection of the pubis symphysis and the left sacroiliac joint. Grimm et al. (15) used forced external rotation to both iliac wings to create

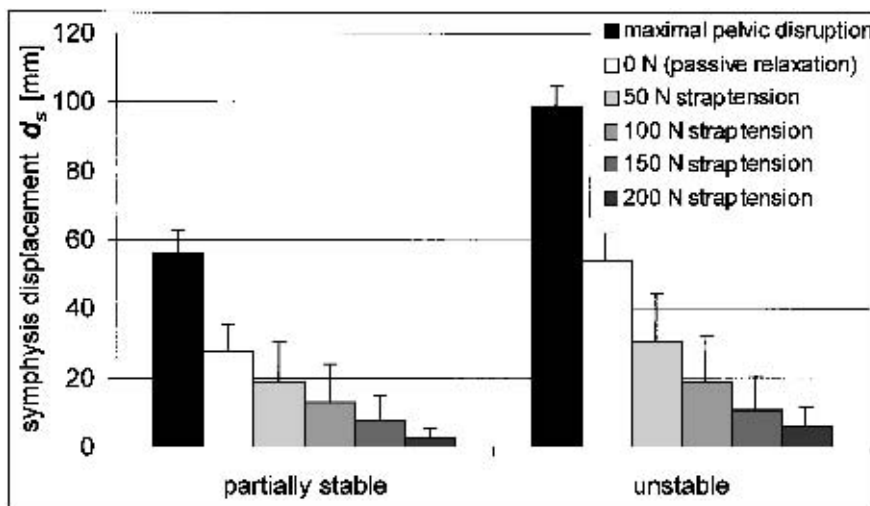


FIG. 6. Symphyseal displacement at maximum pelvic disruption, at sixty seconds after passive relaxation, and after application of pelvic circumferential compression under strap tension up to 200 Newtons.

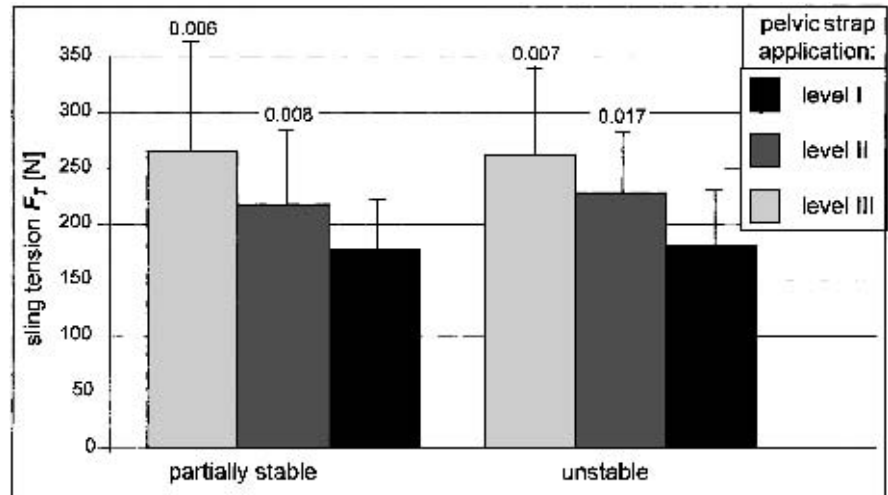


FIG. 7. Effect of strap application level on the strap tension required to induce reduction of partially stable and unstable open-book fractures. Reduction was defined by symphysis contact as indicated by the symphysis contact sensor.

open-book pelvic fractures. After unsuccessful fracture attempts in some specimens, further disruption was facilitated by transection of the pubis symphysis. Expanding on the Grimm et al. (15) experience, we created a consecutive open-book fracture model, simulating two distinct injury severity patterns in each specimen. This model delivered for the first time a graded, highly reproducible symphysis diastasis and was essential to systematically assess the effects of strap tension and position on pelvic reduction.

The cadaveric biomechanical study design was well suited to establish optimal application parameters for a

pelvic strap in terms of its most effective application site (i.e., transverse plane, including the pubis symphysis and the greater trochanteric region) and the required strap tension of 180 Newtons. For comparison this tension is equivalent to the force required for lifting an eighteen-kilogram weight. A large amount of passive recoil of the pelvic ring after fracture was consistently observed. This suggests that the actual damage sustained by an individual may be severely underestimated if predicted solely by the magnitude of the diastasis apparent on postinjury radiographs. The reported skin-strap interface pressure of twenty-four millimeters of mercury is directly

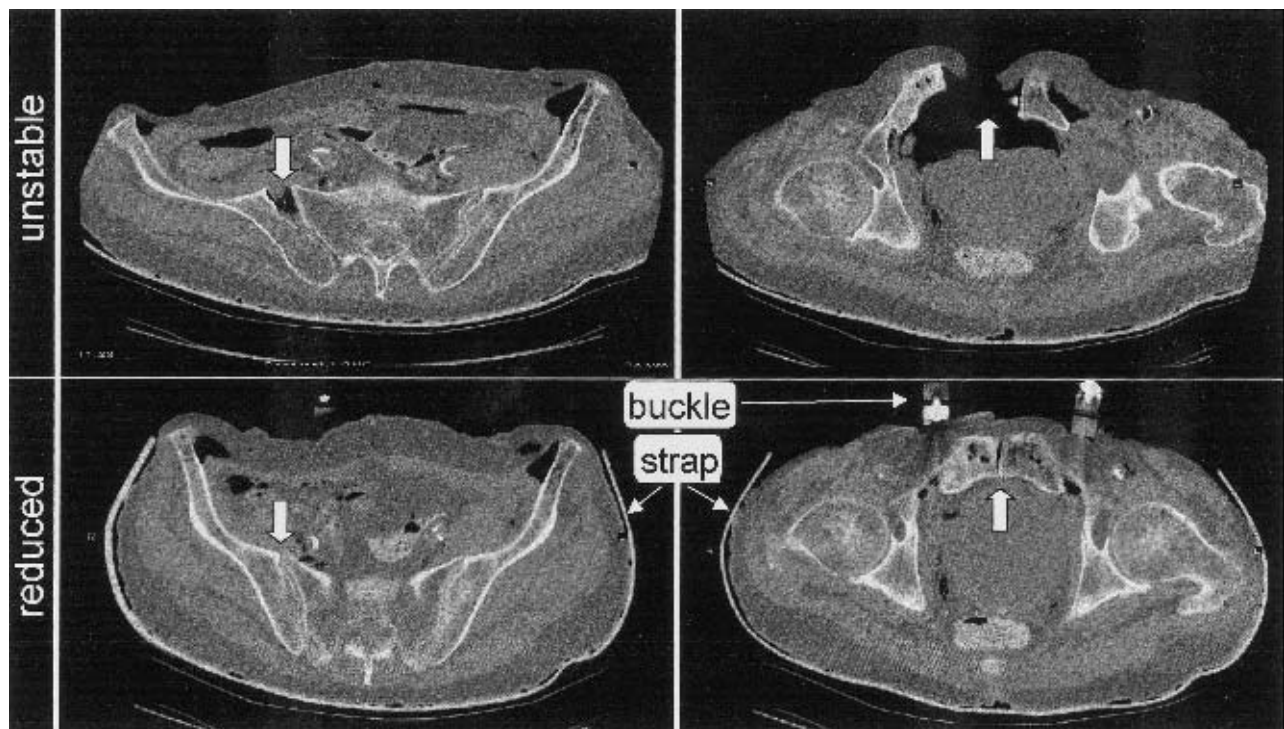


FIG. 8. CT images of a specimen with an unstable open-book pelvic fracture (OTA, Type 61-C1), obtained in two transverse planes before and after application of the pelvic strap at level I.

comparable to the inflation pressure of antishock garments, which typically ranges from twenty to thirty millimeters of mercury. Such garments can be left in place for up to forty-eight hours without causing adverse effects on skin viability (2).

Although this study provides clinically relevant parameters for pelvic strap application, its outcome can only theoretically infer the potential of a pelvic strap to reduce retroperitoneal hemorrhage. However, based on the assumption that early reduction and stabilization of an unstable pelvis are crucial to decrease the extent of retroperitoneal hemorrhage, pelvic straps are likely to provide a highly effective, emergently applicable intervention (3,13,27). Specimen size and weight have not been considered as experimental variables, which confines result interpretation to an adult population within the reported specimen size and weight range. Rendering of the pelvic geometry from CT scans before and after pelvic strap application was obtained for only one specimen. It therefore can serve only as an example to qualitatively visualize pelvic reduction induced by circumferential compression.

Finally, whereas this study provided clinically relevant parameters for pelvic strap application, the results cannot address potential complications associated with a pelvic strap. Further laboratory studies are therefore required to investigate the potential for harm if the pelvic strap is applied at the accident site where the pelvic fracture pattern cannot be reliably assessed. In addition, further investigations should address the effects of patient movement and transportation on the quality of reduction and degree of stabilization over time.

Within these constraints and limitations, the present research delineated key parameters for the provision of emergent pelvic reduction and stabilization with a pelvis strap. These outcome data are directly applicable to advance the clinical concept of circumferential pelvic compression toward a more controlled and effective emergent care procedure.

Acknowledgment: The authors thank Markus Mohr for his assistance.

REFERENCES

- American College of Surgeons. Advanced trauma life support for doctors, ATLS. *Instructor Course Manual* 1997;24:206–209.
- Batalden DJ, Wickstrom PH, Ruiz E. Value of the G suite in patients with severe pelvic fractures. *Arch Surg* 1974;109:326–329.
- Bottlang M, Sigg J, Simpson T, et al. *Emergent Non-invasive Reduction of Pelvic Ring Disruptions*. Chicago: Trans 24th Am Soc Biomech, 2000:45–46.
- Brotman S, Soderstrom CA, Oster-Granite M, et al. Management of severe bleeding in fractures of the pelvis. *Surg Gynecol Obstet* 1981;153:823–826.
- Brown TD, Stone JP, Schuster JH, et al. External fixation of unstable pelvic ring fractures: comparative rigidity of some current frame configurations. *Med Biol Eng Comput* 1982;20:727–733.
- Burgess AR, et al. Pelvic ring disruptions: effective classification system and treatment protocols. *J Trauma* 1990;30:848–856.
- Cryer HM, Miller FB, Evers BM, et al. Pelvic fracture classification: correlation with hemorrhage. *J Trauma* 1988;28:973–980.
- Culemann U, Reilmann H. Injury of the pelvic ring. *Unfallchirurg* 1997;100:487–496.
- Dujardin FH, Hossenbaccus M, Duparc F, et al. Long-term functional prognosis of posterior injuries in high-energy pelvic disruptions. *J Orthop Trauma* 1998;12:145–151.
- Evers M, Cryer H, Miller FB. Pelvic fracture hemorrhage. *Arch Surg* 1989;124:422–424.
- Faillinger MS, McGanity LJ. Current concepts review: unstable fractures of the pelvic ring. *J Bone Joint Surg Am* 1992;74:781–791.
- Flint L, Babikian G, Anders M, et al. Definitive control of mortality from severe pelvic fracture. *Ann Surg* 1990;211:703–707.
- Ganz R, Krushell RJ, Jakob RP, et al. The antishock pelvic clamp. *Clin Orthop* 1991;267:71–78.
- Ghanayem AJ, Wilber JH, Lieberman JM, et al. The effect of laparotomy and external fixator stabilization on pelvic volume in an unstable pelvic injury. *J Trauma* 1995;38:396–401.
- Grimm MR, Vrahas MS, Thomas KA. Pressure-volume characterization of the intact and disrupted pelvic retroperitoneum. *J Trauma* 1998;44:454–459.
- Henry S, Tornetta P, Scalea T. Damage control for devastating pelvic and extremity injuries. *Surg Clin North Am* 1997;77:879–895.
- Jennings TJ, Seaworth JF, Tripp LD. The effects of inflation of antishock trousers on hemodynamics in normovolemic subjects. *J Trauma* 1986;26:544–548.
- Kregor PJ, Routt MLC. Unstable pelvic ring disruptions in unstable patients. *Injury* 1999;30:19–28.
- Lazarus MD, Born CT. Advances in the management of musculoskeletal trauma. *Curr Opin Gen Surg* 1993;46–54.
- Lindahl J, Hervensalo E, Bostman O, et al. Failure of reduction with an external fixator in the management of injuries of the pelvic ring: long term evaluation of 110 patients. *J Bone Joint Surg Br* 1999;81:955–962.
- Mattox KL, Bickell W, Pepe PE, et al. Prospective MAST study in 911 patients. *J Trauma* 1989;29:1104–1112.
- Moreno C, Moore EE, Rosenberger A, et al. Hemorrhage associated with major pelvic fractures: a multispecialty challenge. *J Trauma* 1986;26:987–994.
- Mucha P, Farnell MB. Analysis of pelvic fracture management. *J Trauma* 1984;24:379–386.
- Palmer S, Fairbank AC, Bircher M. Surgical complications and implications of external fixation of pelvic injuries. *Injury* 1997;28:649–653.
- Riemer BL, et al. Acute mortality associated with injuries to the pelvic ring: the role of early patient mobilization and external fixation. *J Trauma* 1993;35:671–677.
- Rothenberger DA, Fischer RP, Perry JF. Major vascular injuries secondary to pelvic fractures: an unsolved clinical problem. *Am J Surg* 1978;136:660–662.
- Routt MLC, Simonian PT, Ballmer F. A rational approach to pelvic trauma: resuscitation and early definitive stabilization. *Clin Orthop* 1995;318:61–74.
- Routt MLC, Simonian PT, Swionkowski MF. Stabilization of pelvic ring disruptions. *Orthop Clin North Am* 1997;28:369–388.
- Sigg J, Bottlang M, Simpson T, et al. *Open Book Pelvic Fractures: Effect of Pelvic Reduction and Hematoma Formation on Retroperitoneal Pressure*. Chicago: Trans 24th Am Soc Biomech, 2000:167–168.
- Simonian PT, Routt MLC, Harrington RM, et al. Internal fixation of the unstable anterior pelvic ring: a biomechanical comparison of standard plating techniques and the retrograde medullary superior pubic ramus screw. *J Orthop Trauma* 1994;8:467–482.
- Simonian PT, Routt MLC, Harrington RM, et al. Anterior versus posterior provisional fixation in the unstable pelvis. *Clin Orthop* 1995;310:245–251.
- Tile M. Pelvic ring fractures: should they be fixed. *J Bone Joint Surg Br* 1988;70:1–12.
- Tile M, Pennal GF. Pelvic disruptions: principles of management. *Clin Orthop* 1980;151:56–64.
- Vermeulen B, Peter R, Hoffmeyer P, et al. Prehospital stabilization of pelvic dislocations: a new strap belt to provide temporary hemodynamic stabilization. *Swiss Surg* 1999;5:43–46.
- Vrahas MS, Wilson SC, Cummings PD, et al. Comparison of fixation methods for preventing pelvic ring expansion. *Orthopedics* 1998;21:285–289.