Case Review

David W. Ross, DO, FACEP, Carol Wichman, BSN, MSN, and Mike MacKinnon, BSN, CEN, CCRN, CCFRN

# Car Versus Bicycle: Conclusion

*A 58-year-old man was riding his bicycle and was struck by a car. He was ejected and landed on his back on the pavement of the roadway. He complained of severe pain in his lower back and sacral area. Ground emergency medical services (EMS) arrived to find a pale, diaphoretic man who was alert but in distress. His medical history was negative, and he was taking no medications. The initial heart rate was 130 beats/minute, and the blood pressure was 70 mmHg by palpation. A helicopter air ambulance was requested from the rural scene location to transport the patient to a trauma center.*

*The physical examination by the flight crew demonstrated the patient had not changed from the original EMS assessment, despite the administration of 1 L normal saline intravenously. There were no apparent injuries to his head, neck, chest, or extremities.*

*Evaluation of the lower lumbar spine demonstrated tenderness without any deformities. Sensation and motor function of the lower extremities appeared to be intact, and no deformity was noted. The pelvis, however, was tender and was questionably unstable. Accordingly, the patient was placed on a long spine board, and a cervical collar was applied. Oxygen by nonrebreather mask was continued. A central line was successfully inserted by the flight crew before departure to provide greater vascular access because of persistent hypotension. Two units of O- blood were started en route. Flight time was 25 minutes.*

*On arrival to the trauma center, prompt workup was commenced. Unstable pelvic fractures were identified, along with a proximal right femur fracture (see Figs.1 and 2). A compressive-sling was applied. External fixation was used later. Unfortunately, despite all efforts, the patient died in surgery.*

## Questions to Consider

### 1. What major injury (or injuries) likely occurred?

Obviously, this is difficult to ascertain in any full detail in the field. However, the history and physical examination suggest the possibility of unstable pelvic fractures. Also the abdominal assessment is not mentioned in the recounting of the field management. Concomitant abdominal injury may be present, but we are not given enough information to know.

### 2. What might have been the cause of death?

Assuming that unstable pelvic fractures are present, the likely cause of death would be exsanguination. In this particular case, the patient also had an extensive liver laceration that resisted surgical control. That and later proven unstable pelvic fractures were believed to have combined to cause death.

### 3. What care should have been provided in the field that is not described, and how is this treatment effective?

When unstable pelvic fractures are believed to be present, some type of compressive sling should be applied to the pelvis by field providers. The various available products and the associated research are discussed later. Although the occurrence of unstable pelvic fractures is relatively rare (3% of all skeletal fractures), compression is a very important technique that may be more important than intravenous fluid/blood replacement to maintain hemodynamics. Compressive slings work by simply reducing the fracture itself and thereby reducing bleeding. Incidentally, hip fractures are not considered pelvic fractures (see following discussion). Therefore, pelvic compression devices have no role in hip fracture management. Additionally, patients with potentially unstable pelvis fractures who are hemodynamically stable, likely do do not need a pelvic compressive device tightened. In these cases, the device should be simply placed around the pelvis in case the patient becomes unstable hemodynamically. But it does not need to be tightened as this generally causes discomfort to awake and alert patient.

### 4. Of the available devices to provide this therapy, is there a difference in efficacy?

The short answer is no. This subject will be discussed in more detail later.

### 5. What treatment is available for this condition at trauma centers?

A variety of options are available. Most have compression slings of some type in the trauma bays that may be

**Figure 1.** Open book pelvic fracture identified in this case (plain x-ray).

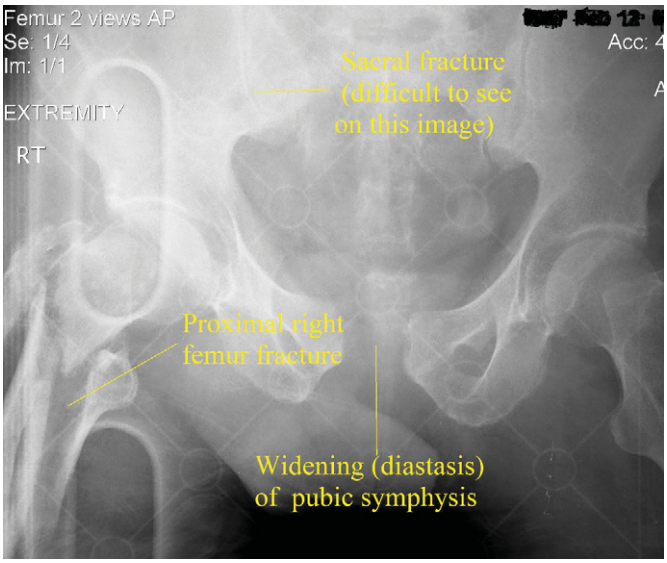


**Figure 2.** Open book pelvic fracture identified in this case (CT scan).

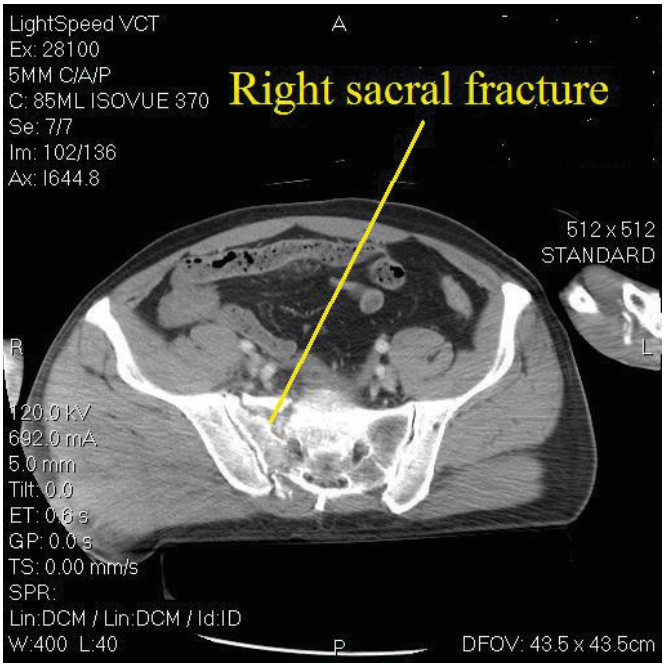


used if not applied in the field, as occurred in this case. Beyond that, other treatment might consist of vascular embolization performed in an angiography suite to reduce bleeding. External fixation may be applied to reduce the fracture and associated bleeding. Open reduction and internal fixation may be used to directly reduce fractures in an operating room environment. A limited number of centers have been using a technique known as preperitoneal packing, which involves opening the space surrounding the bladder and simply placing packing sponges to compress bleeders.

## Discussion

The pelvis is a ring that comprises essentially nine bones tethered by a complex series of ligaments at five dif-

## Reader Responses

RF = Comments from Robert A. Fabich Jr.
ST = Comments from Stephen A. Teitelman
AR = Author responses

**1. What major injury (or injuries) likely occurred?**

RF: I would presume that this patient suffered a pelvic fracture. You can also presume, based on the mechanism of injury, that he may also have some blunt abdominal trauma (lacerated liver, spleen, or kidney injury).

ST: Being that this patient was struck and presumably flew through the air and landed on his back, it sounds like he impacted with a great deal of force to his lumbar spinal area. But more likely the major injury was his pelvis, which was "questionably stable" and tender. Major arteries that sustain injury often in pelvic fractures are the internal iliac, superior gluteal, and lateral sacral artery. It sounds like he had major retroperitoneal bleeding as well.

AR: See text. We agree with most of the above; however, the most common source of major pelvic bleeding in these cases is venous rather than arterial.

**2. What might have been the cause of death?**

RF: Based on the presumed injuries I would assume the cause of death to be hypovolemic shock. Hypovolemia would be a result of a pelvic fracture. I also wonder if there was a potential for a secondary injury such as an MI as a result of poor coronary perfusion from hypovolemia.

ST: Pelvic fracture with major blood loss.

AR: We agree. See text. An associated MI is a good thought but did not occur in this case.

**3. What care should have been provided in the field that is not described and how is this treatment effective?**

RF: Barring no contraindications, MAST trousers could have been used. If this was unavailable, a sheet could have been used to at least stabilize/close the pelvis. MAST trousers are effective by stabilizing the pelvis, increasing systemic vascular resistance, and allowing vital organs to be perfused by reducing blood flow the lower extremities.

ST: From what was described, the patient received full spinal immobilization and even a central line. With a tender pelvis, a commercial pelvic binder device should have been applied.

AR: See text.

**4. Of the devices available to provide this therapy, is there a difference in efficacy?**

RF: Based on the two treatment modes I provided, I would personally use a sheet. This is solely based on the fact that I have very little experience with MAST trousers and that using a sheet to "close the pelvis" seems less controversial than the MAST trousers.

AR: See text.

**5. What treatment is available for this condition at trauma centers?**

RF: The definitive treatment for an unstable pelvic fracture would be surgical intervention. In the management of initial hypovolemia upon arrival to the trauma center, use of a level 1 infuser might be appropriate.

ST: External fixation of the pelvis and immobilization of the damaged arteries to stop the bleeding.

AR: Agreed and see text for more detail.

*The authors thank these readers for their comments.*

*Robert A. Fabich Jr., EMT-I, RN, BSN, CEN, First Lieutenant, US Army Nurse Corps, Fort Bliss, El Paso, TX*

*Stephen A. Teitelman, BS, RN, CEN, CFRN, CCRN, CTRN, Critical Care Transport/Flight RN for JeffSTAT Critical Care Transport Team and Transport Specialist for Temple University Health System Transport Team, Philadelphia, PA*

ferent joints. It takes significant energy to disrupt the ring. Note that a hip fracture is not a pelvic fracture; it is a femur fracture. An acetabular fracture, however, is considered a pelvic fracture.

A combination of fractures or ligament ruptures leads to an unstable pelvis injury. The anatomic proximity of the bladder, rectum, urethra, vagina, and lumbar nerve roots places these organs at risk for injury as well. Because the pelvis is supplied with a rich venous plexus, as well as arteries, unstable pelvic injuries are at risk to produce substantial bleeding. Venous bleeding is most likely to lead to death.

Most simple, uncomplicated pelvic fractures do not result in bleeding or associated organ injury. They occur fairly commonly. An example of a minor pelvic injury unlikely to cause problems, other than pain, is a pubic ramus fracture.

As mentioned, severe pelvic fractures are very infrequent and always involve significant trauma. Common mechanisms in order of occurrence in adults include motor vehicle crashes, motorcycle crashes, pedestrian versus car, and falls. In children, the primary mode of injury is auto versus pedestrian crashes. The overall mortality rate is 10% in adults and 5% in children. Extensive pelvic bleeding is common and is associated with nearly half of the deaths in unstable pelvic fractures. However, retroperitoneal hemorrhage with secondary infection is the primary cause of death in adults and children.

If hypotension is present on arrival to the emergency department, the mortality rate is nearly 50%. If the fracture is open, the mortality rate is 30%. There are several different pelvic fracture classification methods. One of the more commonly used systems is the Young and Burgess Classification,[1] a system essentially based on the mechanism of injury. For example, a patient impacted from the side (or laterally), such as in an auto–pedestrian scenario, would be termed to have a lateral compression (LC) fracture. A patient injured in a head-on auto collision would likely have an anteroposterior (AP) fracture. A patient who fell a long distance would have a vertical shear (VS) type fracture. Some patients may have a combination of injury mechanisms (ie, an LC in combination with an AP or VS). Obviously, a combination type mechanism and injury would have a higher mortality rate. Therefore, a good history from the scene regarding the mechanism of injury is critical in later determining the correct classification of the fracture at the trauma center.

Beyond the mechanism of injury in this classification system, each are graded from I to III based on severity of the fracture and ligament disruption. For example, an LC III or an AP III would portend a higher mortality rate than a lower-graded fracture.

The so-called open book fracture is simply a rotationally unstable pelvic fracture with associated ligament disruption. Open book fractures are classically unstable in rotation but generally vertically stable.

The field assessment in the patient at risk for significant pelvic fractures, as always, begins with the basics of airway, breathing, and circulation checks. The pelvis and perineal areas should be evaluated for obvious external injury including bruising. If the patient is conscious, palpation for tenderness in the pelvic and sacral areas is helpful. At the same time, if the patient can cooperate, a check for motor and sensory function in the lower extremities should be accomplished.

The pelvis may be rocked to check for overall stability, regardless of the patient's level of consciousness. Pulses in the femoral, popliteal, and dorsalis pedis arteries should be assessed bilaterally. Physical assessment is surprisingly good at detecting the presence of significant pelvic injury.[2]

The treatment of complex pelvic fractures in the field begins with management of airway, breathing, and circulatory emergencies. Intravenous access and fluid replacement will be necessary but is not the sole, or primary, means to control hemodynamics in these cases. If intraosseous access is needed, placement should probably be in the humeral head.

As discussed, it is important to use a pelvic compression device. The oldest available device is the pneumatic antishock garment (PASG).[3] Although its use has declined substantially, overall, the abdominal compartment still is an effective stabilization tool for these injuries.

A simple, circumferential sheet can be used as a compressive sling quite effectively.[4,5] Like any of the commercially available slings or the PASG, the sheet should be applied with the lower margin at approximately the level of the femoral heads (greater trochanters). It should be tightened with a knot, or clamp, in the sheet until the operator can just slide two fingers underneath the sheet.

There are three commercial products currently available, to our knowledge. Of the three, only the forerunner of the Sam Sling has been the subject of peer-reviewed studies that we know of. The prototype was evaluated in cadaveric studies of pelvic displacement and reduction by Krieg and associates,[6] who determined that the ideal force to reduce pelvic fractures was 140 to 180 Newtons. An autostop buckle that would reliably produce the pressure needed to approximate the goal was ultimately designed. The prototype was also tested in a series

of clinical experiments on injured patients. Krieg and his coworkers demonstrated that such a sling had reduction capability approaching external fixation.[6-9]

Current Sam Slings come in three different lengths, based on the estimated circumference of the patient's pelvis, and can be reused.

The other two products are the Pelvic Binder and the Trauma Pelvic Orthotic Device. These are similar in design, and both use a corset-like adjustment to vary the tension. They are "one-size-fits-all" slings, and excess material is typically cut to fit smaller patients. They both recommend adjusting tension until two fingers can snugly fit under the sling.

Interestingly, plain radiographs of unstable pelvic fractures treated with any of the above mechanisms, including the PASG and the circumferential sheet, show effective reduction of the bones and pelvic ring.

As pointed out in the literature, this radiographic evidence demonstrates surprisingly good reduction. This suggests that any of the field techniques reviewed here are able to reduce bleeding and stabilize hemodynamics.

As a reminder of this effectiveness, we recently had a patient injured in a motorcycle crash with unstable pelvic fractures who was hypotensive. He failed to respond to initial fluid and blood replacement. However, when a sling device was applied, the blood pressure increased from 70 mmHg systolic to 110 and stayed there until departure to the operating room.

## Conclusion

Unstable pelvic fractures occur relatively rarely. Significant traumatic mechanism is associated with these fractures. Morbidity and mortality are related primarily to associated organ injury and major venous bleeding, as well as nonassociated injuries. A careful physical examination will generally detect the presence of unstable pelvic injuries in the field. Treatment consists of the usual interventions for hypovolemic shock but adds the concept of pelvic compression. EMS crews should assess major mechanism trauma patients for pelvic injuries and, if thought to be present, should apply a compressive sling to assist in the stabilization of hemodynamics.

## References


1. Burgess AR Eastridge BA, Young JW, Ellison TS, Ellison PS Jr, Poka A, Bathon GH, et al. Pelvic ring disruptions: effective classification system and treatment protocols. J Trauma 1990;30:848-56.
2. Gonzalez RP, Fried PQ, Bukhalo M. The utility of clinical examination in screening for pelvic fractures in blunt trauma. J Am Coll Surg 2002;194:121-5.
3. Mattox KL, Bickell W, Pepe PE, Burch J, Feliciano D. Prospective MAST study in 911 patients. J Trauma 1989;29:1104-12.
4. Routt MLC, Simonian PT, Swiontkowski MF. Stabilization of pelvic ring disruptions. Orthop Clin North Am 1997;28:369-88.
5. Simspon T, Krieg JC, Heuer F, Bottlang M. Stabilization of pelvic ring disruptions with a circumferential sheet. J Trauma 2002;52:158-161.
6. Krieg JC, Mohr M, Ellis TJ, Simpson TS, Madey SM, Bottlang M. Emergent stabilization of pelvic ring injuries by controlled circumferential compression: a clinical trial. J Trauma 2005;59:659-64.
7. Bootlang M, Krieg JC, Mohr M, Simpson TS, Madey SM. Emergent management of pelvic ring fractures with the use of circumferential compression. J Bone Joint Surg Am 2002;84A(Suppl 2):43-7.
8. Bottlang M, Simpson T, Sigg J, Krieg JC, Madey SM, Long WB. Noinvasive reduction of open-book pelvic fractures by circumferential compression. J Orthop Trauma 2002;16:367-73.
9. Krieg JC, Mohr M, Mirza AJ, Bottlang M. Pelvic circumferential compression in the presence of soft tissue injuries: a case report. J Trauma 2005;59:470-2.



*David W. Ross, DO, FACEP, is a former flight medical director and the current medical director of numerous ground EMS agencies in the Colorado Springs area. An emergency physician at Penrose Hospital, he can be reached at* DRDR0682@aol.com. *Carol Wichman, BSN, MSN, a former flight nurse, has been a site reviewer for the Commission on Accreditation for Medical Transport Systems (CAMTS) and has authored a number or articles and textbook chapters. Mike MacKinnon, BSN, CEN, CCRN, CCFRN, is a flight nurse and a former paramedic trained in Nova Scotia, Canada. He created and maintains an interactive case review series at www.flightweb.com.*


*Authors' Note: For a variety of reasons, this article marks our final contribution to the Case Review Series in Air Medical Journal. We would like to thank the authors who have contributed cases for this series, as well as the readers we have received comments from, during the 4 years it has been published. We hope that this series and its format have been beneficial.*


1067-991X/$36.00


Copyright 2009 by Air Medical Journal Associates


doi:10.1016/j.amj.2009.08.004